

Damage-Control Surgery for Obstetric Hemorrhage

Luis D. Pacheco, MD, M. James Lozada, DO, George R. Saade, MD, and Gary D. V. Hankins, MD

Damage-control surgery (abdominopelvic packing followed by a period of medical stabilization in the intensive care unit) is a life-saving intervention usually reserved for critically injured patients who may not survive an attempt to achieve hemostasis and complete repair of the damage in the operating room. Most obstetricians have little or no experience in this area, although the use of damage-control surgery in selected cases may be life-saving. This approach should be considered when arterial bleeding has been controlled and persistent bleeding is deemed to be secondary to coagulopathy that is refractory to blood product replacement, particularly in the presence of hypothermia, acidosis, and vasopressor requirement. A prototypical (albeit hypothetical) case is described here in which damage-control surgery is indicated.

(*Obstet Gynecol* 2018;132:423–7)

DOI: 10.1097/AOG.0000000000002743

In a prototypical case, a 33-year-old patient with a diagnosis of placenta percreta undergoes a scheduled cesarean hysterectomy at 35 weeks of gestation. Intraoperatively, there is evidence of placental invasion of the bladder and the left broad ligament. As a result of massive blood loss, a massive transfusion of

packed red blood cells, fresh-frozen plasma, and platelets is initiated in a 1:1:1 ratio. After completion of the procedure, there is evidence of diffuse oozing from the surgical site with a serum fibrinogen level of 74 mg/dL, platelet count of 31,000/mm³, temperature of 34°C, and arterial pH of 7.13. A decision is made to pack the abdomen and pelvis and transfer the patient to the surgical intensive care unit for further resuscitation and medical treatment of the coagulopathy.

INTRODUCTION

Damage-control surgery is a well-established life-saving management approach in trauma and other surgical specialties.¹ Damage-control surgery is usually reserved for the critically injured patient who may not survive an attempt to achieve hemostasis and complete repair of the damage in the operating room. In these patients, the bleeding cannot be controlled surgically, mostly because of a combination of hypothermia, acidosis, coagulopathy, and hypocalcemia.

In these situations, temporizing measures aimed at slowing the bleeding are better than continuing futile attempts in the operating room that further exacerbate the reasons for the refractory bleeding. The same approaches used in a damage-control surgery in trauma and other specialties can be applied in obstetrics. However, most obstetricians have little or no experience in this area. In this article, we provide an approach to the intraoperative management of obstetric patients with uncontrolled intraabdominal hemorrhages that is modeled after the approaches used in damage-control surgery and provide guidance on their subsequent medical management in the intensive care unit (ICU).

SURGICAL DAMAGE CONTROL

Damage-control surgery consists of performing a limited surgical intervention to immediately abate life-threatening conditions (eg, bleeding, contamination from bowel injury) with definitive surgical control deferred until a period of medical stabilization has been completed in the ICU.² It is key that all bleeding

From the Departments of Obstetrics & Gynecology and Anesthesiology, the University of Texas Medical Branch, Galveston, Texas; and the Division of Obstetrical Anesthesiology, Department of Anesthesiology, Vanderbilt University Medical Center, Nashville, Tennessee.

Each author has indicated that he has met the journal's requirements for authorship.

Received March 27, 2018. Received in revised form May 16, 2018. Accepted May 17, 2018.

Corresponding author: Luis D. Pacheco, MD, The University of Texas Medical Branch at Galveston, 301 University Boulevard, Galveston, TX 77555-0587; email: ldpachec@utmb.edu.

Financial Disclosure

The authors did not report any potential conflicts of interest.

© 2018 by the American College of Obstetricians and Gynecologists. Published by Wolters Kluwer Health, Inc. All rights reserved.

ISSN: 0029-7844/18



sources amenable to surgical intervention (eg, arterial bleeding) should be controlled before considering a damage-control procedure. In many cases, massive transfusion protocols have already been activated without improvements in the severity of bleeding. Common indications for damage-control surgery resulting from bleeding include difficult access to the bleeding site, venous bleeding not amenable to surgical control, persistent intraoperative blood product and fluid requirements in the setting of nonarterial bleeding, hemodynamic instability, and development of ventricular arrhythmias, and coagulopathy resulting from a combination of hypothermia, acidosis, and loss of clotting factors.^{3,4} Typically, these patients develop persistent diffuse oozing in the absence of formed clots in the operative field despite maximal surgical efforts. The usual indications for damage-control surgery secondary to bleeding are summarized in Box 1.

As in damage-control surgery in other surgical fields, packing is the cornerstone of damage control in obstetric patients. Most surgeons pack the abdomen and pelvis with conventional sterile laparotomy pads.⁵ The pads should be placed directly over the bleeding surfaces with sufficient pressure to stop the bleeding. Excessive pressure, however, may result in increased intraabdominal pressure, resulting in abdominal compartment syndrome (discussed later).⁶ In cases with an open vaginal cuff, a pelvic umbrella pressure pack exiting the vagina has been described as an effective measure to control bleeding.⁷ The evidence regarding the addition of hemostatic agents, either directly on the tissue or already included in the pads, is limited. In a retrospective review of trauma patients, Choron et al⁵ compared the use of usual laparotomy pads or pads or gauze impregnated with kaolin (combat gauze and trauma pad) and found no additional benefit over packing alone. We have found that in some cases, the

addition of hemostatic agents such as thrombin spray or fibrin glue may be a useful approach to limit ongoing bleeding together with packing.

Despite no consensus regarding the use of prophylactic antibiotics while packing is in place, some recommend their use.⁸ In our institution, we use broad-spectrum antibiotics, usually a second-generation cephalosporin (eg, 2 g cefoxitin intravenously every 6 hours) until the packing is removed. In patients allergic to β -lactam agents, the combination of levofloxacin (500 mg intravenously daily) with metronidazole (500 mg intravenously every 8 hours) may be used. We discourage the use of aminoglycosides in this setting as a result of the risk of acute kidney injury.

Once packed, it is imperative to monitor for signs of intraabdominal hypertension, including difficulty ventilating the patient (usually clinically evident as elevated peak airway pressures secondary to cephalad displacement of the diaphragm), unexplained hemodynamic instability (secondary to increased inferior vena cava compression with decreased preload and cardiac output), and oliguria.

Because the abdominal closure is temporary, the ideal method should be easy to apply and remove, protect the abdominal contents from evisceration, prevent development of enteroatmospheric fistulas, and prevent lateral retraction of the fascia, because the latter may result in inability to complete definitive abdominal wall closure when the patient returns to the operating room. Although some surgeons may decide to close the fascia after packing, we caution that this intervention may raise intraabdominal pressure significantly resulting in the development of abdominal compartment syndrome. The simplest method of abdominal closure is approximating the skin with sutures or towel clips. This technique, however, may result in skin damage, and the risk of evisceration is high.⁹

Another popular and inexpensive method involves the use of a plastic silo constructed from a 3-L sterile urology irrigation plastic bag, also known as the "Bogota bag." The latter is simply sutured to the edges of the fascia allowing temporary closure.² The Bogota bag may cause injury to the fascia, and the risk of evisceration remains significant.⁹ More recently, the use of negative pressure wound therapy devices has allowed for continuous fluid collection from the cavity (decreasing edema and ascites) while maintaining tension on the fascia, allowing higher rates of primary fascial closure.^{10,11} These devices may be safely placed in patients with an open abdomen by using a visceral protective layer (commercially available

Box 1. Common Intraoperative Indications for Damage-Control Surgery Secondary to Bleeding

- Venous bleeding not amenable to surgical control
- Persistent bleeding despite transfusion of large amounts of blood products (greater than 10 units packed red cells)
- Persistent and escalating fluid requirements in the setting of active nonarterial bleeding
- Hemodynamic instability or development of ventricular arrhythmias
- Coagulopathy resulting from a combination of hypothermia (temperature less than 35°C), acidosis (pH less than 7.3), and loss of clotting factors



with the vacuum device) that is placed between the exposed viscera and the foam layer of the device. The use of vacuum-assisted closure has been associated with improved survival and higher delayed fascial closure success compared with other temporary closure techniques.¹² We favor the use of negative pressure vacuum devices for temporary abdominal wall closure where available.

There is limited evidence regarding the timing for reoperation, either to remove or replace the intra-abdominal packing. Most experts agree that early removal (within 24 hours) may result in serious rebleeding and should be avoided.¹ On the other hand, leaving packs for longer than 72 hours is consistently associated with more complications from infection (eg, abdominal abscess formation).¹³ Provided the patient is stable and physiologic derangements have been corrected (temperature, pH, electrolyte anomalies, and coagulopathy), the optimal time to remove the pack appears to be between days 2 and 3 postoperatively.¹ Obviously, it is best to time the reoperation when the coagulopathy has been reversed. In most cases, the operation may be performed by an experienced obstetrician.

ROLE OF SURGICAL DAMAGE CONTROL IN OBSTETRICS

Several obstetric conditions may benefit from damage-control surgery such as persistent bleeding from placenta accreta, ruptured liver hematomas associated with preeclampsia, and attempts at placental removal in cases of abdominal ectopic pregnancies. As expected, the available literature involving abdominal-pelvic packing in obstetrics is limited to a few case series (PubMed review from 1990 until present using the terms control surgery, pregnancy, hemorrhage). In a recent mail survey study from South Africa including more than 1 million deliveries, 1 of every 14 peripartum hysterectomies was treated with abdominal packing.¹⁴ Despite the limited available data, obstetric patients requiring damage-control surgery resulting from postpartum hemorrhage should be managed following the same principles as in nonpregnant individuals.

POSTOPERATIVE CARE

Most patients who have intraabdominal packing should remain mechanically ventilated and are best cared for in an ICU involving a multidisciplinary team. If packing occurs in a setting of limited resources (eg, limited blood bank capacity), in hemodynamically stable patients, with no evidence of

further bleeding, transfer to a higher level of care facility may be considered.

In the ICU, the main objective should be to manage all the conditions that are likely to contribute to the ongoing coagulopathy. Excessive crystalloid (or colloid) administration should be avoided because it will contribute to hypothermia and dilutional coagulopathy and worsen third spacing (mainly crystalloids), which will increase intraabdominal pressure.¹⁵ Platelet transfusion is recommended for levels below 50,000/mm³ in the presence of active bleeding. Similarly, in the setting of ongoing bleeding, the serum fibrinogen should be maintained above 150 mg/dL and ideally above 200 mg/dL.¹⁶ The latter may be accomplished with the use of cryoprecipitate or fibrinogen concentrates (where available). Conventional bleeding times (eg, prothrombin time and activated partial thromboplastin time) should be kept in the normal range with the use of fresh-frozen plasma and cryoprecipitates.

The use of viscoelastic tests (eg, thromboelastography or thromboelastogram) to guide blood product transfusions and adjuvant pharmacologic agents such as tranexamic acid may be considered when there is ongoing bleeding. Importantly, in a hemodynamically stable patient without active bleeding, a blood product transfusion for the purpose of correcting laboratory values alone should be avoided.

Hypocalcemia (secondary to chelation from citrate contained in blood products) can impair coagulation and should be corrected. Massive transfusion may result in hyperkalemia, which, if present, needs aggressive treatment. Warming the patient—most commonly with the use of surface warming devices such as the Bair Hugger—is imperative to allow optimal clotting function.¹⁷

Metabolic acidosis is usually the result of lactate accumulation and will improve with correction of tissue perfusion and coagulopathy. In most cases, the use of sodium bicarbonate is not needed.

Conventional critical care management, including lung-protective mechanical ventilation, targeted sedation with daily spontaneous breathing trials, early enteral feeding (which is not contraindicated in the setting of an open abdomen), and thromboembolism prophylaxis (mechanical until bleeding risk is decreased), should be applied routinely. The use of enteral feeding in the setting of an open abdomen results in improved rates of successful fascial closure and fewer complications from infection, likely as a result of decreased intestinal bacterial translocation.⁹

In the setting of an open abdomen, analgesia and sedation are required because most patients will be



receiving mechanical ventilation; however, pharmacologic paralysis is not mandatory.⁹ The ICU management of the patient with an open abdomen is depicted in Figure 1.

ABDOMINAL COMPARTMENT SYNDROME

Pregnancy is a state of chronically elevated intra-abdominal pressure. The median intraabdominal pressure during late pregnancy is reported to range between 15 and 29 mm Hg. It decreases to a median pressure of 16 mm Hg at 24 hours postpartum.^{18,19} Critically ill pregnant patients have a median intra-abdominal pressure ranging from 7.8 to 14.1 mm Hg on the day of ICU admission.²⁰ Consequently, pregnant or postpartum patients will have a higher baseline intraabdominal pressure and should not be treated based on an isolated measurement in the absence of clinical findings consistent with abdominal compartment syndrome.

As mentioned previously, abdominal compartment syndrome may occur in the setting of an open abdomen when packing is excessive and tight or secondary to either a massive bowel edema after overzealous crystalloid resuscitation or hematoma formation. Abdominal compartment syndrome usually manifests with hypotension and oliguria not

Box 2. Intravesical Pressure Measurement Technique

- Patient must be in the supine position
- Attach commercially available measurement device to Foley catheter
- Distend bladder with up to 25 mL of saline
- Wait 60 sec
- Zero pressure transducer at level of the midaxillary line at the iliac crest
- Document pressure at end of expiration

responsive to fluid therapy together with a distended abdomen and high peak pressures on the ventilator. The diagnosis must be confirmed with a surrogate measurement of abdominal pressure. The latter is usually accomplished using intravesical pressure.²¹ The technique recommended to measure intravesical pressure is described in Box 2.

Once the diagnosis is confirmed, definite treatment involves opening the fascia to allow for decompression. In the setting of damage-control surgery, the fascia is already open. In cases in which the fascia opening is too small, extension of the incision may decrease the pressure within the abdomen. If the packing is too tight, the clinician may consider repacking the patient; however, the risk of bleeding

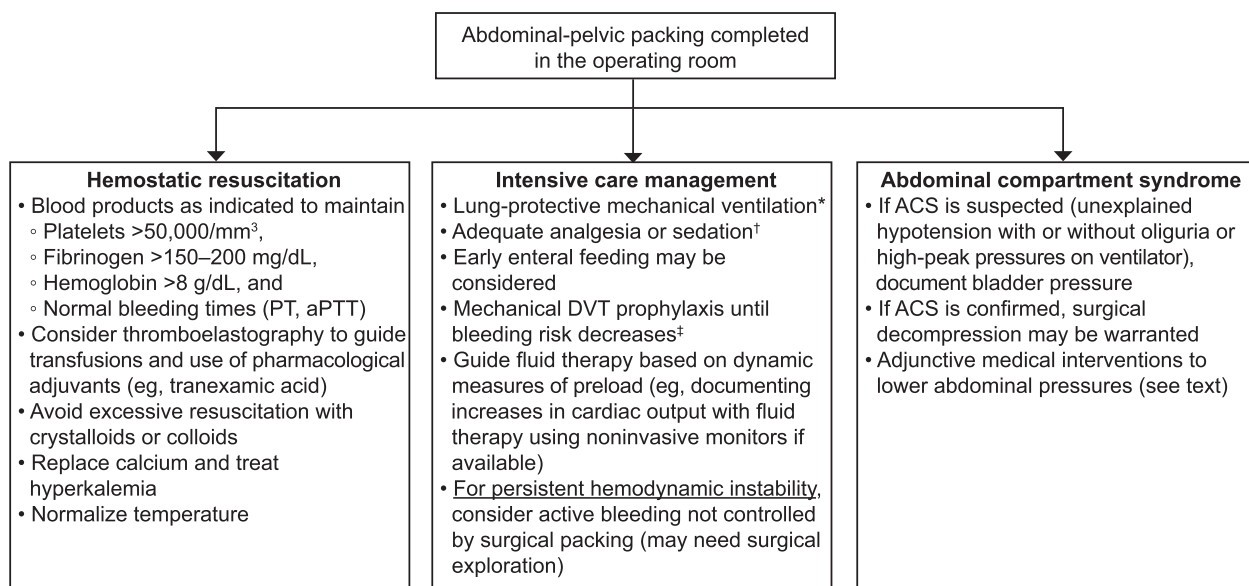


Fig. 1. Intensive care unit management after damage control for obstetric bleeding. *Tidal volume of 6 mL/kg ideal body weight with plateau pressure below 30 cm H₂O. [†]Start with a narcotic infusion such as fentanyl (50–200 micrograms/h) or hydromorphone (0.2–2.0 mg/h). If required, a sedative may be added such as propofol (5–50 micrograms/kg/min), dexmedetomidine (0.2–1.5 micrograms/kg/h), or midazolam (1–10 mg/h). If paralysis is required, use cisatracurium at 2–4 micrograms/kg/min. [‡]Initially use sequential compression devices. Once bleeding risk decreases may transition to pharmacologic prophylaxis. PTT, partial thromboplastin time; aPTT, activated partial thromboplastin time; DVT, deep vein thrombosis; ACS, abdominal compartment syndrome.

Pacheco. *Damage-Control Surgery for Obstetric Hemorrhage*. *Obstet Gynecol* 2018.



with removal of the original pack must be considered. Certain medical interventions may lower intraabdominal pressures, including the use of an oral or nasogastric tube, rectal tube, gastrointestinal prokinetic agents, diuretics, and pharmacologic paralysis (allowing a decrease in the abdominal wall muscle tone). The latter interventions should not substitute for surgical treatment when indicated.

DISCUSSION

In obstetric patients who have experienced massive hemorrhage, damage-control surgery should be considered when arterial bleeding has been controlled and persistent bleeding is deemed to be secondary to coagulopathy that is refractory to blood product replacement, particularly in the presence of hypothermia, acidosis, and vasopressor requirement.

REFERENCES

- Ordoñez C, Pino L, Badiel M, Sanchez A, Loaiza J, Ramirez O, et al. The 1-2-3 approach to abdominal packing. *World J Surg* 2012;36:2761-6.
- Cocolini F, Biffl W, Catena F, Ceresoli M, Chiara O, Cimbanassi S, et al. The open abdomen, indications, management and definite closure. *World J Emerg Surg* 2015 Jul 25 [Epub ahead of print].
- Benz D, Balogh ZJ. Damage control surgery: current state and future directions. *Curr Opin Crit Care* 2017;23:491-7.
- Lamb CM, MacGoey P, Navarro AP, Brooks AJ. Damage control surgery in the era of damage control resuscitation. *Br J Anaesth* 2014;113:242-9.
- Choron RL, Hazelton JP, Hunter K, Capano-Wehrle L, Gaughan J, Chovanes J, et al. Intra-abdominal packing with laparotomy pads and QuickClot™ during damage control laparotomy: a safety analysis. *Injury* 2017;48:158-64.
- Santhosh MCB, Pai RB, Sachidanand R, Byrappa V, Rao RP. Inferior vena cava compression due to excessive abdominal packing. *Braz J Anesthesiol* 2014;64:199-200.
- Dildy GA, Scott JR, Saffer CS, Belfort MA. An effective pressure pack for severe pelvic hemorrhage. *Obstet Gynecol* 2006;108:1222-6.
- Adam DJ, Fitridge RA, Raptis S. Intra-abdominal packing for uncontrollable hemorrhage during ruptured abdominal aortic aneurysm repair. *Eur J Vasc Endovasc* 2005;30:516-9.
- Sartelli M, Abu-Zidan FM, Ansaloni L, Bala M, Belrán MA, Biffl WL, et al. The role of open abdomen procedure in managing severe sepsis: WSES position paper. *World J Emerg Surg* 2015;10:35.
- Brock WB, Barker DE, Burns RP. Temporary closure of open abdominal wounds: the vacuum pack. *Am Surg* 1995;61:30-5.
- Cheatham ML, Demetrides D, Fabian TC, Kaplan MJ, Miles WS, Schreiber MA. Prospective study examining clinical outcomes associated with negative pressure wound therapy system and Barker's vacuum packing technique. *World J Surg* 2013;37:2018-30.
- Yanar H, Sivrikoz E. Management of open abdomen: single center experience. *Gastroenterol Res Pract* 2013 Nov 17 [Epub].
- Abikhaleh JA, Granchi TS, Wall MJ, Hirshberg A, Mattox KL. Prolonged abdominal packing for trauma is associated with increased morbidity and mortality. *Am Surg* 1997;63:1109-12.
- Deffieux X, Vinchant M, Wigniolle I, Goffinet F, Sentilhes L. Maternal outcome after abdominal packing for uncontrolled postpartum hemorrhage despite peripartum hysterectomy. *PLoS One* 2017;12:e0177092.
- Stewart RM, Park PK, Hunt JP, McIntyre RC Jr, McCarthy J, Zarzabal LA, et al. Less is more: improved outcomes in surgical patients with conservative fluid administration and central venous catheter monitoring. *J Am Coll Surg* 2009;208:725-35.
- Pacheco LD, Saade GR, Costantine MM, Clark SL, Hankins GD. An update on the use of massive transfusion protocols in obstetrics. *Am J Obstet Gynecol* 2016;214:340-4.
- Dutton WD, Diaz JJ Jr, Miller RS. Critical care issues in managing complex open abdominal wound. *J Intensive Care Med* 2012;27:161-71.
- Chun R, Kirkpatrick AW. Intra-abdominal pressure, intra-abdominal hypertension, and pregnancy: a review. *Ann Intensive Care* 2012 Jul 5;5(suppl 1):S5.
- Fuchs F, Bruyere M, Senat MV, Purenne E, Benhamou D, Fernandez H. Are standard intra-abdominal pressure values different during pregnancy? *PLoS One* 2013;8:e77324.
- Tyagi A, Singh S, Kumar M, Sethi AK. Intra-abdominal pressure and intra-abdominal hypertension in critically ill obstetrical patients: a prospective cohort study. *Int J Obstet Anesth* 2017;32:33-40.
- Kirkpatrick AW, Roberts DJ, De Waele J, Jaeschke R, Malbrain ML, De Keulenaer B, et al. Intra-abdominal hypertension and the abdominal compartment syndrome: updated consensus definitions and clinical practice guidelines from the World Society of the Abdominal Compartment Syndrome. *Intensive Care Med* 2013;39:1190-206.

